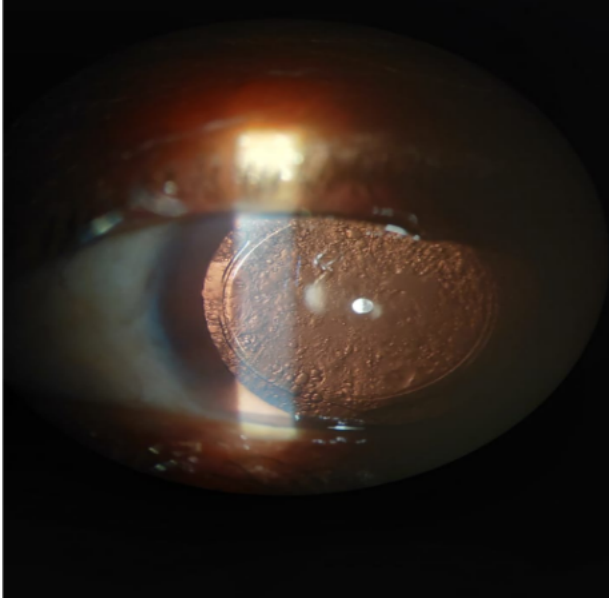




Case Briefing



A 65 year old man comes to the Out Patient Department with complaints of progressive painless visual blurring in his left eye since last 3 months; sometimes associated with Glare and Monocular diplopia. He has a history of SICS +PCIOL implantation; 8 years back in both eyes. His Vision in left eye is now 6/60 (with glasses); which previously was 6/6 (with glasses).The slit lamp examination shows the following (image given).

1.What is your provisional diagnosis?

Answer-Elschnig Pearls.

It's is Post Capsular opacification; caused by the ballooning of the left out epithelial cells. They

are seen in slit lamp examination.

2.How will you treat this pateint?

Answer-If asymptomatic no treatment required.

If in optic axis causes dimness of vision; Nd YAG laser to remove the opacification.

