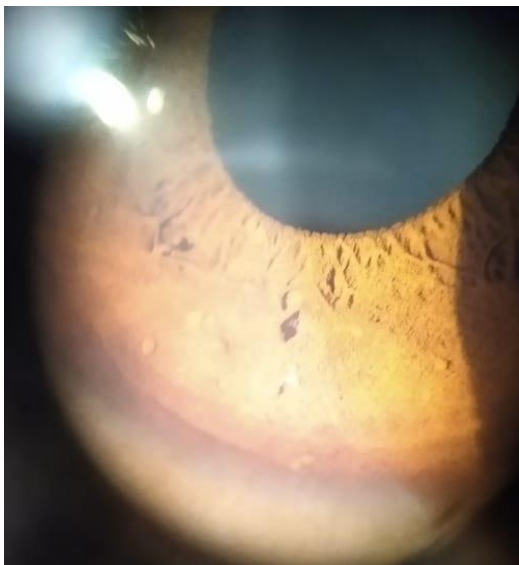




**A 19 year old male patient comes with multiple nodular lesions all over his body; he also complains of learning disabilities since childhood.**

**In Ophthalmology OPD; you do a slit lamp examination and get this picture.**



- 1. What is the ocular finding?*
- 2. What is the probable diagnosis?*
- 3. What more will you like to look for from Ophthalmology point of view?*

**Answer :-**

- 1.)Lisch nodules over iris**
- 2.) Neurofibromatosis.**
- 3.)Associated finding Optic nerve Glioma.**